

CLINICAL RESEARCH

Reliability of a three-dimensional facial camera for dental and medical applications: A pilot study

Shiming Liu, DMD,^a Murali Srinivasan, Dr med dent, BDS, MDS, MBA, MAS,^b Roland Mörzinger, MSc,^c Marcel Lancelle, PhD,^d Thabo Beeler, PhD,^e Markus Gross, Prof PhD,^f Barbara Solenthaler, PhD,^g Vincent Fehmer, MDT,^h and Irena Sailer, Prof Dr med dentⁱ

Surgical or prosthetic rehabilitations often lead to significant changes in the patient's facial appearance. Visualization of the intended outcome is necessary to evaluate the treatment plan before the start and increases the predictability of the clinical procedures.¹ Some visualization of the planned changes can be accomplished by modifying the diagnostic casts with diagnostic waxing or trial restorations with pre-fabricated resin teeth for completely or partially edentulous patients.^{2,3} Virtual diagnostic visualization can be accomplished by importing 2D extraoral and intraoral images into a presentation software program and then simulating the treatment outcomes virtually, thus enabling

ABSTRACT

Statement of problem. Three-dimensional visualization for pretreatment diagnostics and treatment planning is necessary for surgical and prosthetic rehabilitations. The reliability of a novel 3D facial camera is unclear.

Purpose. The purpose of this clinical study was to evaluate the reliability of a novel medical facial camera system in capturing the 3D geometry of the face in a single exposure.

Material and methods. Twelve edentulous participants (7 women and 5 men; mean age: 74.6 years) were included, and digital images for facial reconstruction were captured using a custom-made static capturing system (Medusa Static; Disney Research Zurich). Eight extraoral soft-tissue facial landmarks were identified, which included the right outer canthus (OCR), left outer canthus (OCL), right cheilion (CmR), left cheilion (CmL), pronasale nostril tip, subnasale, philtrum, and gnathion (GN). Interlandmark distances of OCR-OCL, OCR-CmR, OCL-CmL, OCR-GN, OCL-GN, CmR-CmL, pronasale nostril tip-GN, and subnasale-GN were measured clinically and then on the 3D digital reconstructions. The absolute differences between the digital and clinical measurements were recorded. The intraclass correlation coefficient was applied to evaluate the reliability of digital measurement and interexaminer reliability.

Results. The mean \pm standard deviation difference between the clinical and digital measurements was 1.95 ± 0.33 mm. Intraclass correlation coefficients computed for the 2 examiners against clinical measurements were all above 0.5. The interexaminer reliability coefficient of digital measurement was above 0.909.

Conclusions. The 3D facial geometry obtained from the novel medical facial camera system was found to be reliable and clinically acceptable. Inconsistencies in measurements for a few specific facial landmarks may arise, but these can be avoided by thorough examiner calibration before undertaking the digital measurements. (J Prosthet Dent 2018;■:■-■)

S.L. and M.S. contributed equally to this article. This study was partly supported by the CTI grant 15151.2 PFEF-ES and the Division of Fixed Prosthodontics and Biomaterials, University Clinics of Dental Medicine, University of Geneva, Geneva, Switzerland.

^aAttending Dentist, First Clinic Division, School and Hospital of Stomatology, Peking University, Beijing, PR China.

^bResearch and Teaching Fellow, Division of Gerodontology and Removable Prosthodontics, University Clinics of Dental Medicine, University of Geneva, Geneva, Switzerland.

^cResearch Engineer, Computer Graphics Laboratory, Federal Technical Institute of Technology, Zurich, Switzerland.

^dPost-doctorate Scientist, Computer Graphics Laboratory, Federal Technical Institute of Technology, Zurich, Switzerland.

^eSenior Research Scientist, Disney Research Zurich, Zurich, Switzerland.

^fHead, Computer Graphics Laboratory, Federal Technical Institute of Technology, Zurich, Switzerland.

^gSenior Research Scientist, Computer Graphics Laboratory, Federal Technical Institute of Technology, Zurich, Switzerland.

^hMaster Dental Technician, University Clinic of Dental Medicine, University of Geneva, Geneva, Switzerland.

ⁱHead, Division of Fixed Prosthodontics and Biomaterials, University Clinics of Dental Medicine, University of Geneva, Geneva, Switzerland.

Clinical Implications

Three-dimensional facial reconstruction of patients is a useful tool that can aid practitioners in diagnosis and treatment planning. Integrating intraoral captures into 3D facial images can greatly improve the efficacy and quality of the overall therapeutic outcome.

patients to evaluate the treatment outcome.⁴⁻⁶ Limitations of 2D virtual diagnostics are that it only allows modification of the intraoral environment⁷ but does not fully show modifications to the extraoral appearance.^{8,9} Hence, 3D visualization and planning tools to predict or visualize the definitive treatment outcome of dental rehabilitations are desirable.^{10,11}

Different 3D facial scanning methods have been introduced which include laser scanning,¹² structured light technology,^{13,14} and stereophotogrammetry.¹⁵⁻¹⁷ However, these are currently only used for the visualization of the pretreatment situation and are not yet sufficiently developed to integrate with other forms and sources of anatomic data (such as intraoral scans and 3D radiographs) to simulate the end effect of a proposed dental or medical treatment. A novel static facial camera system was used in the present study for capturing the 3D geometry of the face with an ultrahigh accuracy in a single photogrammetric stereo imaging exposure.¹⁸ The resulting 3D mesh constructed further allowed matching with other forms and sources of digital data to enable accurate virtual diagnostics. This technology was originally developed in a joint project by Disney Research Zurich and the ETH Computer Graphics Laboratory in Zurich for use in the entertainment industry.¹⁸

The purpose of this pilot clinical study was to evaluate the reliability of this new 3D medical facial camera system for capturing patients' image in a dental environment. The null hypotheses were that the distance between different landmarks measured on a 3D reconstruction would not correspond to the values obtained with the analog clinical measurements and that these measurements on the 3D reconstructions by different operators would not be reliable.

MATERIAL AND METHODS

Twelve completely edentulous individuals (7 women and 5 men, mean age: 74.6 years) rehabilitated with removable complete denture prostheses consented to participate in this pilot study. Ethical approval was obtained from the ethics committee of the University Hospitals of Geneva (CCER no.: 15-161). The participants were informed about the purpose of the

study and the associated procedures, and written informed consents were obtained.

The facial camera system consisted of 6 individual digital single lens reflex (D-SLR) cameras (Canon EOS 1200D; Canon Europe Ltd) with 60-mm lenses (Canon EF-S 60 mm f/2.8 Macro USM; Canon Europe Ltd) arranged around the participant in a fixed configuration. They were used to capture facial images to construct the 3D facial geometry.¹⁸ The system captured multiple images in a single exposure from different angles (Fig. 1). Neighboring camera pairs subtended an angle of about 20 degrees at the head, and the outermost cameras subtended an angle of about 110 degrees. The cameras were able to synchronize up to 0.1 seconds, which is sufficient for static subjects. The participants were coached on how to perform and maintain the required facial expressions during the image-capturing process. Image matching and stereographic refinement was performed pairwise between neighboring cameras to generate a pore-scale 3D facial geometry. The technology combined photogrammetric cues with concepts from depth-from-shading in a holistic optimization framework. Technical details of those systems and the arrangement have been described previously.¹⁸

Eight soft-tissue landmarks, which included, right outer canthus (OCR), left outer canthus (OCL), pronasale nostril tip, subnasale, philtrum, gnathion (GN), left cheilion (CmL), and right cheilion (CmR), were identified and marked on the participant's face (Fig. 2). The following interlandmark distances, OCR-OCL, OCR-CmR, OCR-GN, OCL-CmL, OCL-GN, CmR-CmL, pronasale nostril tip-GN, and subnasale-GN, were measured clinically using a conventional analog measuring caliper (Inox; Knuth GmbH) that was precise to 0.01 mm. For the analog clinical measurements, participants were asked to sit upright, to keep their eyes open, and to occlude with the prosthesis at centric occlusion (CO) (serious state in CO). The distances between defined landmarks were measured 3 consecutive times. The distance of OCR-GN was calculated as the sum of the distances of OCR-CmR and CmR-GN, and the same method was used for measuring the distance of OCL-GN.

The participants were then photographed with the camera arrangement with the prostheses in situ, the same facial expression (serious state in CO), and in the same position as described for the analog measurements. The 3D reconstructions were based on the stereophotogrammetric algorithm, and they are exported in the Polygon File Format.¹⁸ For digital measurements of the distances between landmarks in the 3D constructions, a 3D mesh-processing software program (Meshlab; <http://meshlab.sourceforge.net/>) was used. The interlandmark distances in the 3D constructions were measured 3 times consecutively by 2 examiners (S.L., M.S.), who were

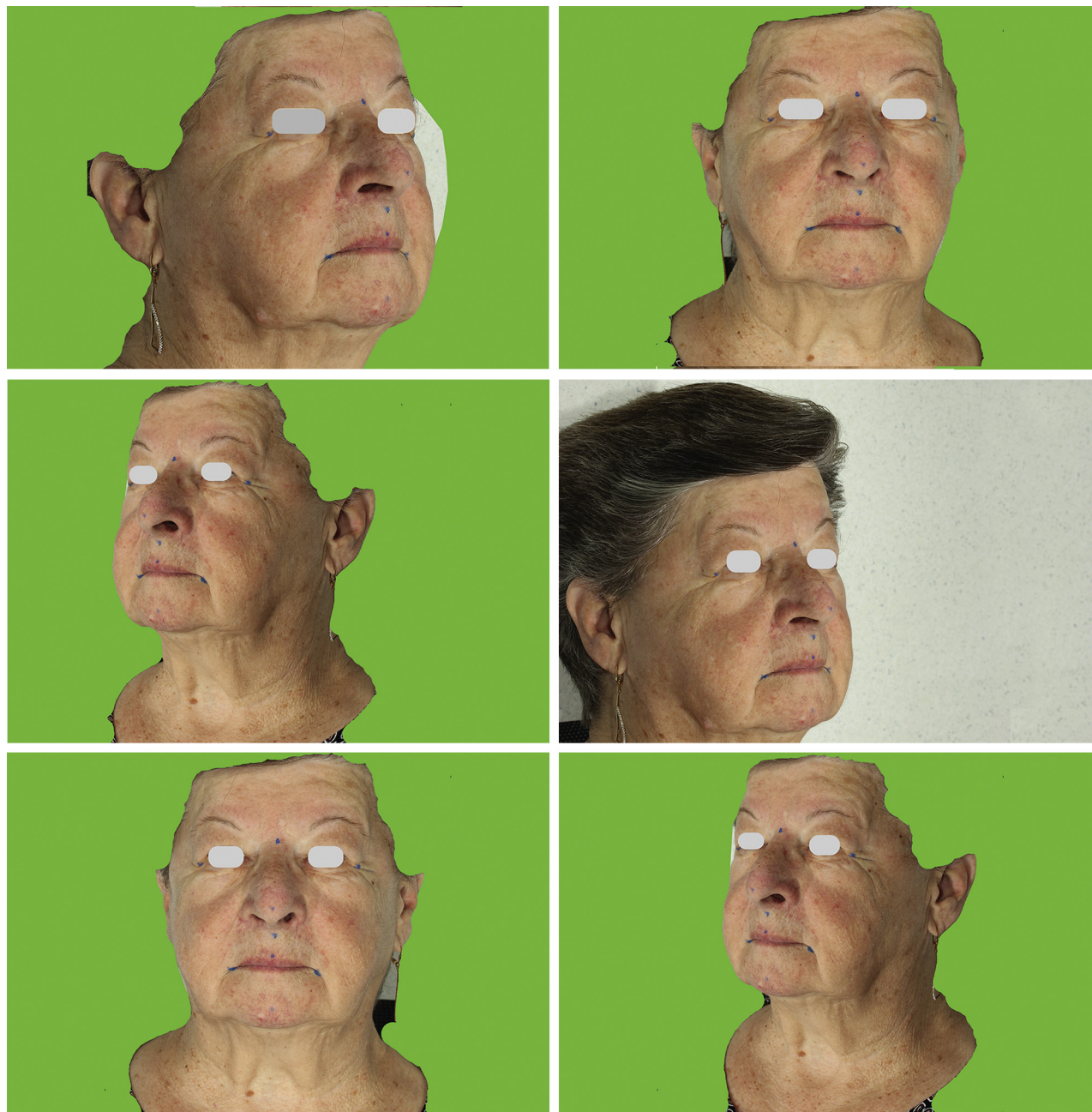


Figure 1. Representative images of participant in single shot.

blinded to the other's measurements. The second examiner (M.S.) had also made the earlier clinical measurements.

The mean and standard deviation of the analog and digital measurements by the 2 examiners were calculated for each of the 12 participants. To quantify the inter-examiner reliability, the intraclass correlation coefficient (ICC) was computed between examiners for each landmark. The clinical measurements were used as the gold standard, and the absolute differences between the clinical measurement and digital measurement were

analyzed. ICC was computed for each examiner against the clinical measurement. The reliability of the measurement was considered excellent with ICC greater than 0.80 and considered good with ICC in the range of 0.50 to 0.80. The absolute difference between the analog clinical and digital measurement by different examiners was computed and analyzed. The nonparametric Kruskal-Wallis test was applied to evaluate the differences between different landmarks. Statistical analysis of data was performed using a statistical software program (IBM SPSS Statistics, v24.0; IBM Corp) ($\alpha=.05$).

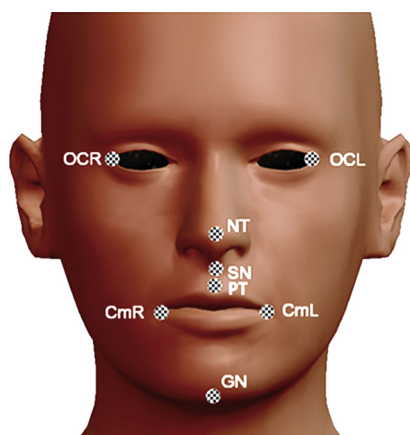


Figure 2. Defined landmarks: right outer canthus (OCR), left outer canthus (OCL), pronasale nostril tip (NT), subnasale (SN), philtrum (PT), gnathion (GN), left cheilion (CmL) and right cheilion (CmR).

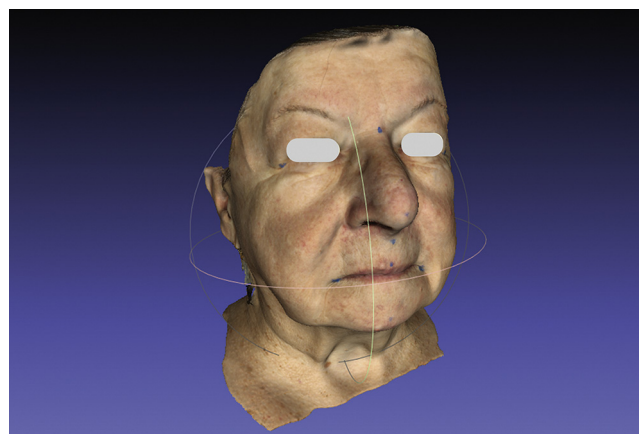


Figure 3. Three-dimensional geometry of participant with prosthesis in serious state in maximum intercuspal position.

Table 1. Mean \pm standard deviation value of analog clinical and digital measurements for each interlandmark (mm)

Interlandmark	Clinical Measurement	Digital Measurement	
		Examiner 1	Examiner 2*
OCR-OCL	118.64 \pm 7.30	119.56 \pm 7.78	119.73 \pm 7.72
OCR-CmR	68.75 \pm 4.46	69.72 \pm 4.03	69.28 \pm 3.45
OCR-GN	112.06 \pm 9.09	115.15 \pm 7.64	114.65 \pm 7.08
OCL-CmL	68.01 \pm 3.08	69.47 \pm 3.58	69.17 \pm 3.22
OCL-GN	111.53 \pm 5.31	117.33 \pm 5.86	116.73 \pm 5.80
CmR-CmL	59.36 \pm 5.87	61.88 \pm 5.40	60.98 \pm 5.79
NT-GN	65.58 \pm 4.60	66.38 \pm 4.02	66.79 \pm 4.63
SN-GN	48.36 \pm 5.04	49.41 \pm 3.58	49.65 \pm 4.31

CmL, left cheilion; CmR, right cheilion; GN, gnathion; NT, pronasale nostril tip; OCL, left outer canthus; OCR, right outer canthus; PT, philtrum; SN, subnasale. *Also performed clinical measurements.

RESULTS

A total of twelve 3D constructions, 1 per participant, based on multiple images captured by the test camera arrangement were generated. The 3D images displayed the participants in a serious state in CO with the prostheses in situ (Fig. 3).

The mean \pm standard deviation values of the clinical and digital measurements of the interlandmark distances are shown in Table 1. The mean absolute differences between digital measurements by 2 examiners were all below 1 mm. The interexaminer reliability for each landmark is presented in Table 2, with the lowest ICC at 0.908 for landmark 2. The mean ICCs were all different (all $P < .01$, paired t test), the interexaminer ICC was the highest, and clinical-digital examiner 1 was the lowest.

A comparison of the digital measurements against the clinical measurements revealed the mean absolute difference between the clinical and digital measurements to be 1.95 ± 0.33 mm. At landmark OCR-GN and OCL-GN, the difference between clinical and digital measurements

Table 2. Interexaminer reliability and reliability of digital measurements by 2 examiners

Interlandmark	Interdigital Examiner	ICC	
		Clinical-Digital Examiner 1	Clinical-Digital Examiner 2
OCR-OCL	0.988	0.944	0.948
OCR-CmR	0.908	0.787	0.829
OCR-GN	0.966	0.777	0.812
OCL-CmL	0.959	0.531	0.659
OCL-GN	0.971	0.517	0.596
CmR-CmL	0.942	0.815	0.928
NT-GN	0.923	0.686	0.822
SN-GN	0.952	0.647	0.755
Mean	0.951	0.730	0.794

CmL, left cheilion; CmR, right cheilion; GN, gnathion; ICC, intraclass correlation coefficient; NT, pronasale nostril tip; OCL, left outer canthus; OCR, right outer canthus; PT, philtrum; SN, subnasale.

was larger than the other interlandmark distances (Kruskal-Wallis $P < .01$ for examiner 1 and $P = .02$ for examiner 2; confirmed using multiple Mann-Whitney tests) (Fig. 4).

The reliability of digital measurements by examiner 1 and 2 was good, with ICC over 0.5 in all the measurements. Landmarks OCL-CmL and OCL-GN were the least reliable, with ICC values between 0.5 and 0.6.

DISCUSSION

The null hypotheses that the distances between different landmarks measured on 3D reconstruction would not correspond to the values obtained with the analog clinical measurements and that these measurements on the 3D reconstructions by different examiners would not be reliable were rejected. The digital measurements of the novel 3D facial camera were reliable when compared with the analog clinical measurements.

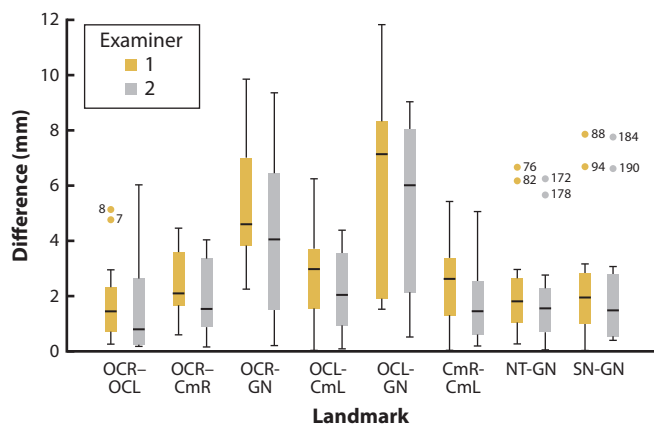


Figure 4. Absolute difference between analog clinical and digital measurements for each interlandmark (mm). Error bars indicate standard deviations. CmL, left cheilion; CmR, right cheilion; GN, gnathion; NT, pronasale nostril tip; OCL, left outer canthus; OCR, right outer canthus; PT, philtrum; SN, subnasale.

The mean absolute differences of the interlandmark distances of OCR-GN and OCL-GN were higher than the other results. This finding can be explained by the muscular movement at the angles of the mouth (cheilions), which may have caused difficulty achieving high precision for the facial reconstruction or matching the 3D models from the repeated scanning. For the distance of OCR-GN (sum of OCR-CmR and CmR-GN) and OCL-GN (sum of OCL-CmL and CmL-GN), the micro-muscular movement of bilateral cheilions could double the effect on the difference between analog clinical and digital measurements. This finding is consistent with that of other studies that have reported that 3D facial photographs were accurately reproducible, except for the cheek and mouth regions.^{11-14,19,20}

Studies comparing the differences between the measurements on 3D facial constructions and physical models or clinical participants have found that the mean difference between the 3D scanning images and clinical participants ranged from 0.22 ± 0.1 mm to 1.20 ± 0.46 mm.¹⁵ Ma et al¹⁶ found the mean difference between the 3D reconstruction and physical model to be 0.93 ± 0.36 mm. Weinberg et al²¹ reported that the mean error of linear measurement between physical and digital casts was less than 1 mm, which can be regarded as an acceptable threshold. The mean absolute difference between the analog clinical and digital measurements was 1.95 ± 0.33 mm, slightly greater than these published studies, and landmarks OCR-GN and OCL-GN produced larger error. Without these 2 landmarks, the absolute difference between clinical and digital measurements in the present study is comparable with that of these previous studies.^{15,16}

The facial capture system has been used in the motion picture and game industries.¹⁸ A study of this camera

system and its capturing method measured the error between 3D geometry created by the camera system and the physical mask that was created by fabricating a gypsum cast of the face. The absolute error between the physical mask and 3D image was 0.88 ± 0.12 mm.

The present pilot study registered several landmarks on the faces of participants as shown in Figure 2. Studies on facial scans have questioned whether it was useful to apply landmarks or anatomic structures for measurement and comparison.^{14,16,19,20,22} The main difficulty in using anatomic structures is the difficulty for several examiners to locate exactly the same target position.^{14,16} In the present study, the diameter of landmarks was quite large, and the center of each landmark was not easy to recognize. This could explain why 1 of the examiners was less reliable in the measurement of 2 landmarks (OCL-CmL and OCL-GN), although the interexaminer reliability was excellent.

The results of this pilot study are limited to the single 3D image of every participant. Further evaluation of the present method would involve repeated 3D photographs of the participants and verification of the differences between multiple images from the same participant.

CONCLUSIONS

Within the limitations of this clinical pilot study, the following conclusions were drawn:

1. Three-dimensional facial geometry using the novel medical facial camera system was found to be reliable and clinically acceptable.
2. Inconsistencies in measurements for a few specific facial landmarks may arise, but these can be avoided by thorough examiner calibration before undertaking the digital measurements.

REFERENCES

1. Magne P, Magne M, Belser U. The diagnostic template: a key element to the comprehensive esthetic treatment concept. *Int J Periodontics Restorative Dent* 1996;16:560-9.
2. Magne M, Magne I, Magne P. Diagnostic waxing transfer from diagnostic casts to soft tissue definitive casts. *J Prosthet Dent* 2008;100:70-1.
3. Sancho-Puchades M, Fehmer V, Hämmerle C, Sailer I. Advanced smile diagnostics using CAD/CAM mock-ups. *Int J Esthet Dent* 2015;10:374-91.
4. McLaren EA, Schoenbaum T. Digital photography enhances diagnostics, communication, and documentation. *Compend Contin Educ Dent* 2011;32 Spec No 4:36-8.
5. Coachman C, Calamita M. Digital Smile Design – a tool for treatment planning and communication in esthetic dentistry. *Quintessence Dent Technol* 2012;35:1-9.
6. Kurbad A, Kurbad S. Cerec Smile Design—a software tool for the enhancement of restorations in the esthetic zone. *Int J Comput Dent* 2013;16:255-69.
7. Terajima M, Furuichi Y, Aoki Y, Goto TK, Tokumori K, Nakasima A. A 3-dimensional method for analyzing facial soft-tissue morphology of patients with jaw deformities. *Am J Orthod Dentofacial Orthop* 2009;135:715-22.
8. Ayoub AF, Xiao Y, Khambay B, Siebert JP, Hadley D. Towards building a photo-realistic virtual human face for craniomaxillofacial diagnosis and treatment planning. *Int J Oral Maxillofac Surg* 2007;36:423-8.
9. Girod S, Keeve E, Girod B. Advances in interactive craniofacial surgery planning by 3-D simulation and visualization. *Int J Oral Maxillofac Surg* 1995;24(1 Pt 2):120-5.

10. Maal TJ, Plooiij JM, Rangel FA, Mollemans W, Schutyser FA, Berge SJ. The accuracy of matching three-dimensional photographs with skin surfaces derived from cone-beam computed tomography. *Int J Oral Maxillofac Surg* 2008;37:641-6.
11. Maal TJ, Verhamme LM, van Loon B, Plooiij JM, Rangel FA, Kho A, et al. Variation of the face in rest using 3-D stereophotogrammetry. *Int J Oral Maxillofac Surg* 2011;40:1252-7.
12. Nord F, Ferjencik R, Seifert B, Lanzer M, Gander T, Matthews F, et al. The 3-D MD photogrammetric photo system in cranio-maxillofacial surgery: validation of interexaminer variations and perceptions. *J Craniomaxillofac Surg* 2015;43:1798-803.
13. Metzler P, Sun Y, Zemann W, Bartella A, Lehner M, Obwegeser JA, et al. Validity of the 3-D VECTRA photogrammetric surface imaging system for cranio-maxillofacial anthropometric measurements. *Oral Maxillofac Surg* 2014;18:297-304.
14. Verhoeven T, Xi T, Schreurs R, Bergé S, Maal T. Quantification of facial asymmetry: a comparative study of landmark-based and surface-based registrations. *J Craniomaxillofac Surg* 2016;44:1131-6.
15. Kau CH, Richmond S, Zhurov A, Ovsenik M, Tawfik W, Borbely P, et al. Use of 3-dimensional surface acquisition to study facial morphology in 5 populations. *Am J Orthod Dentofacial Orthop* 2010;137:S56.e1-9.
16. Ma L, Xu T, Lin J. Validation of a three-dimensional facial scanning system based on structured light techniques. *Comput Methods Programs Biomed* 2009;94:290-8.
17. Paul SM, Chamberlin AP, Hatt C, Nayak AV, Danoff JV. Reliability, validity, and precision of an active stereophotogrammetry system for three-dimensional evaluation of the human torso. *Med Eng Phys* 2009;31:1337-42.
18. Beeler T, Bickel B, Beardsley P, Sumner B, Gross M. High-quality single shot capture of facial geometry. *ACM Trans Graph* 2010;29(40):1-9.
19. Ye H, Lv L, Liu Y, Liu Y, Zhou Y. Evaluation of the accuracy, reliability, and reproducibility of two different 3-D face-scanning systems. *Int J Prosthodont* 2016;29:213-8.
20. Dindaroglu F, Kutlu P, Duran GS, Gorgulu S, Aslan E. Accuracy and reliability of 3-D stereophotogrammetry: a comparison to direct anthropometry and 2-D photogrammetry. *Angle Orthod* 2016;86:487-94.
21. Weinberg SM, Naidoo S, Govier DP, Martin RA, Kane AA, Marazita ML. Anthropometric precision and accuracy of digital three-dimensional photogrammetry: comparing the Genex and 3dMD imaging systems with one another and with direct anthropometry. *J Craniofac Surg* 2006;17:477-83.
22. Schimmel M, Christou P, Houstis O, Herrmann FR, Kiliaridis S, Müller F. Distances between facial landmarks can be measured accurately with a new digital 3-dimensional video system. *Am J Orthod Dentofacial Orthop* 2010;137:580.e1-10.

Corresponding author:

Dr Irena Sailer
 Division of Fixed Prosthodontics and Biomaterials
 University Clinics of Dental Medicine, CMU, University of Geneva
 1, rue Michel-Servet
 1211 Geneva 4
 SWITZERLAND
 Email: irena.sailer@unige.ch

Copyright © 2018 by the Editorial Council for *The Journal of Prosthetic Dentistry*.
<https://doi.org/10.1016/j.prosdent.2018.10.016>